

The Theory

- Very logical
- Why throw out the entire femoral head when only the surface is diseased?
- Its ancestors actually preceded THR
- Serious problems with materials
- With new hard bearing technology is it time to re-examine the concept?

McMinn Metal on Metal Resurfacing

- Non surface coated press-fit femur and cup
 - Both components were cobalt chrome
 - 70 hips beginning in 1991 with ave f/u 50 mo
 - 61 satisfactory and 6 (8.6%) with aseptic loosening



McMinn et al; CORR Number 329S, 1996

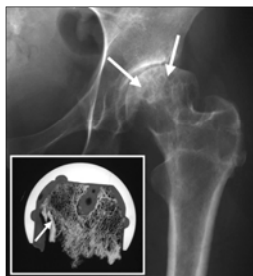Risk Factors for Failure

- Varus of femoral component **CTQ**
 - Failed femurs - 128° (110°-148°)
 - Non failed femurs – 136.2° (111°-163°)
 - p=.0255
- Large cystic areas of head (5 hips) **CTQ**
- Failure to seat femoral component (3) **CTQ**
- Femoral notching
 - Amstutz JBJS Sept 2004

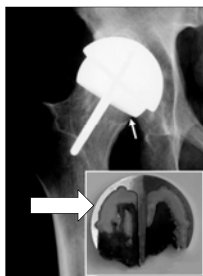
Australian Registry

- Improved survivorship of Birmingham Hip resurfacing arthroplasty vs. THR in young males

Cystic changes

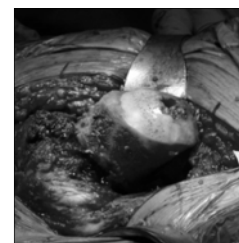
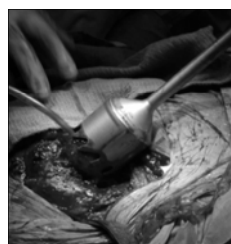


Femoral component not seated

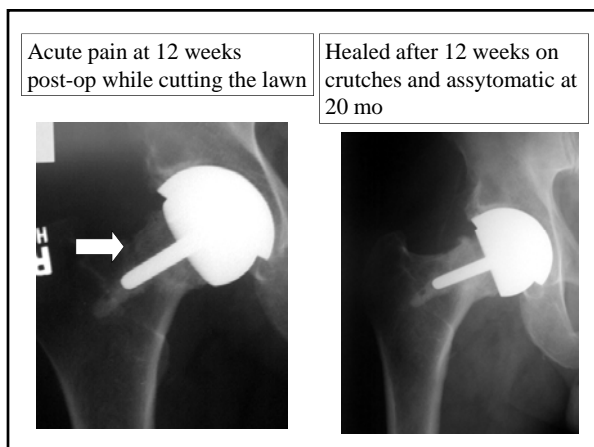
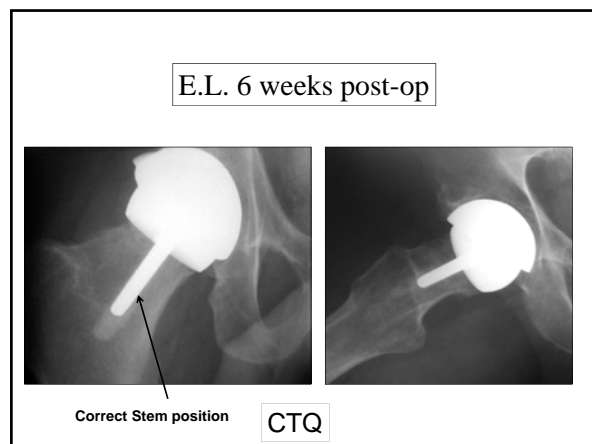
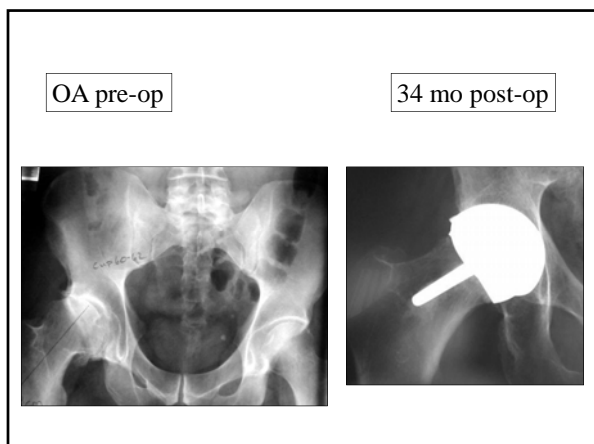


Amstutz JBJS Sept 2004

Precise femoral reaming



Stem should be parallel to calcar, not centered on neck! **CTQ**



- ### ALVAL/ Pseudo tumor
- Aseptic Lymphocytic Vasculitis Associated Lesions
 - B and T cell Lymphocyte infiltrates seen in small numbers of patients with MOM articulations
 - More common in females
 - Thought to be a metal hypersensitivity distinct from delayed type hypersensitivity
 - Patients have pain
 - Associated with vertical cup

- ### Neck Thinning
- Thought to be stress shielding
 - Unknown consequences
 - Patients don't have pain
-

- ### Summary
- Hip resurfacing is procedure that has traditionally failed secondary to material deficiencies largely on the cup side
 - AVN under the cup is still a concern, but several studies suggest that this is not a problem
 - The experience with hemi resurfacing seems to support the durability of the femoral side

Summary

- Metal on metal designs should resolve many of the acetabular issues
- These designs carry with them all the same concerns regarding ion levels of all MOM hips
- The procedure is **very technically** demanding and has several unique failure modes as compared to total hip replacement