

# Osteogenesis Imperfecta: OITE Review

Arabella Leet, MD  
Johns Hopkins University  
Department of Orthopedics

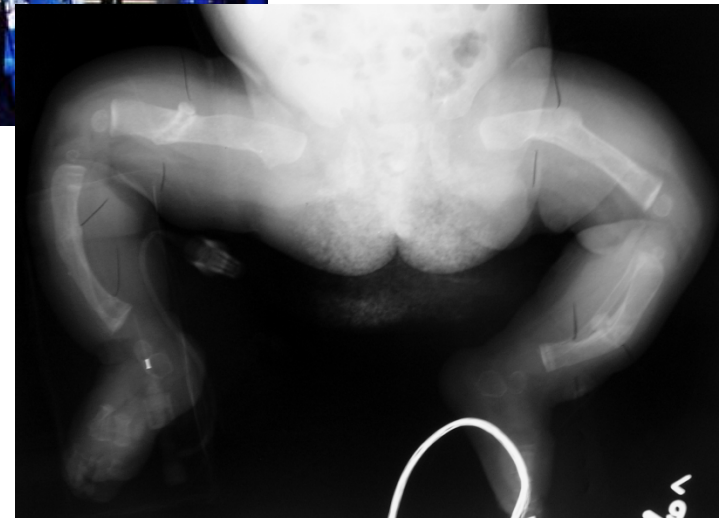
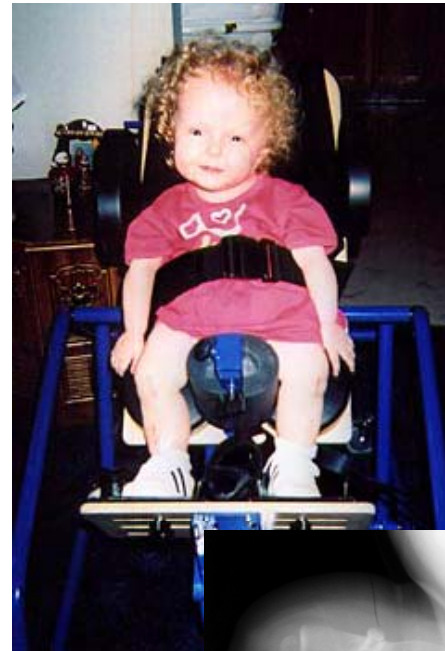# Disclosures

- Research Funding:
  - OI Foundation
  - POSNA
- Non-FDA approved Uses of Medication:
  - Pamidronate (Bisphosphonates)

What are the clinical features  
of OI?

# Clinical features of OI

- Birth fractures
- Blue sclera
- Wormian skull bones
- Short stature
- Deformity of the spine and limbs
- Muscle weakness



What is the gene disorder?

# Complex Genetic Disorder

- Multiple genotypes
  - (300+)
  - Not all genes are on COLA1 but most are.
- Poor genotype to phenotype correlation



How is OI classified?

# Silence Classification

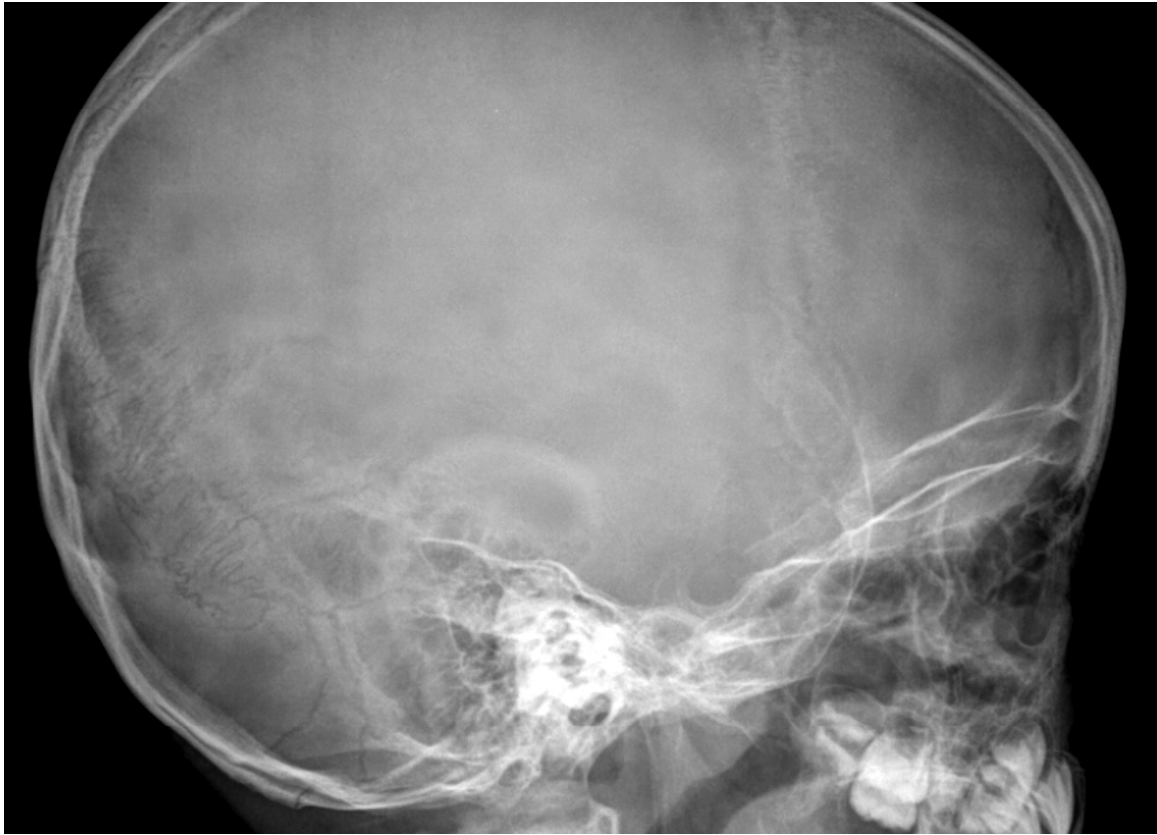- Type 1 tarda
  - Type 2 lethal
  - Type 3 “typical”
  - Type 4 all else
- Also types 5-9

What distinguishes OI from  
child abuse?

# History of injury probably most important!

## also

- OI if wormian skull bones, low bone density (greater than age 2), testing for OI positive: blood now used more commonly than skin biopsy.
- Child abuse if corner fractures, or other signs of shaking (retinal exam, CT head etc.)

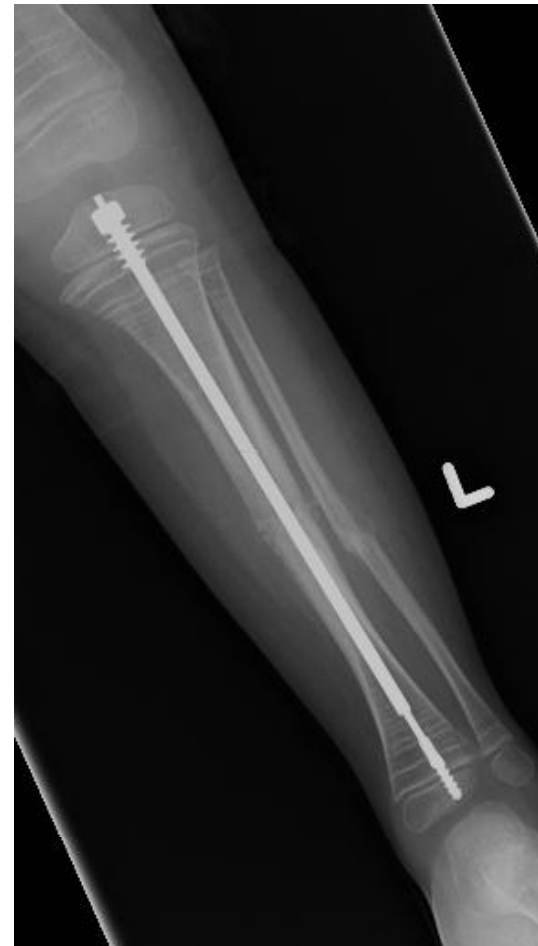
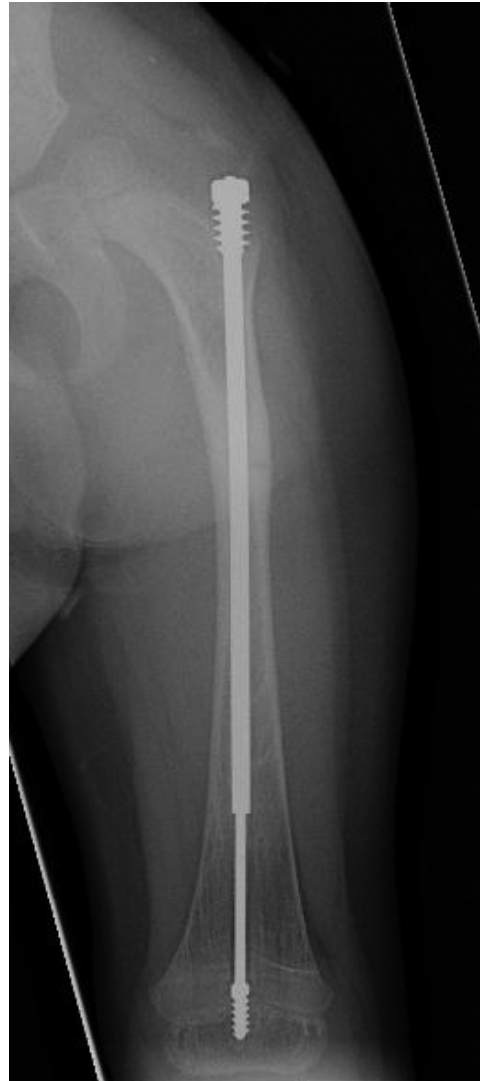

How is OI treated surgically?

# Surgical Treatment of Fracture or Deformity

- Only IM devices
- Fractures will occur at the end of plates or screws so these devices are avoided
- Telescopic rods are used more frequently than solid rods
- Indications for rodding: multiple fractures in the same location, size and medical status conducive to rodding

# New Rod: Fassier-Duval Telescopic Rod (10 yr)



# POSNA 2010: Larson et al

- “High reoperation rate and failed expansion in LE expandable Rods in OI”
- In complete healing 61%
- Loss of fixation 57% in 2 years

# Avoid prolonged casting and disuse

- Remove splints/casts asap when callus
- Begin aqua therapy or letting children get up as tolerated as early as possible

What is the current medical  
management of OI in  
children?

CYCLIC ADMINISTRATION OF PAMIDRONATE THERAPY IN CHILDREN WITH SEVERE OSTEOGENESIS IMPERFECTA

CYCLIC ADMINISTRATION OF PAMIDRONATE IN CHILDREN WITH SEVERE  
OSTEOGENESIS IMPERFECTA

FRANCIS H. GLORIFIX, M.D., PH.D., NICHOLAS J. BISHOP, M.D., HORACIO PLOTKIN, M.D., GILLES CHAROT, M.D.,  
GINETTE LANOUE, R.N., AND ROSE TRAVERS, R.T.

The New England Journal of Medicine

Volume 339 Number 14

**1998**

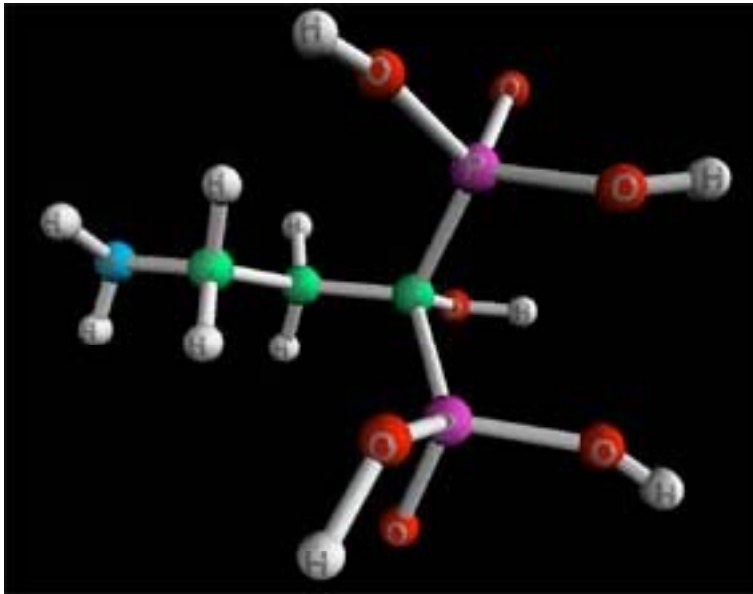
Decreased pain

Increased growth

Increased bone density

Not a significant change in fracture rate

# New Medical Treatment: Bisphosphonates



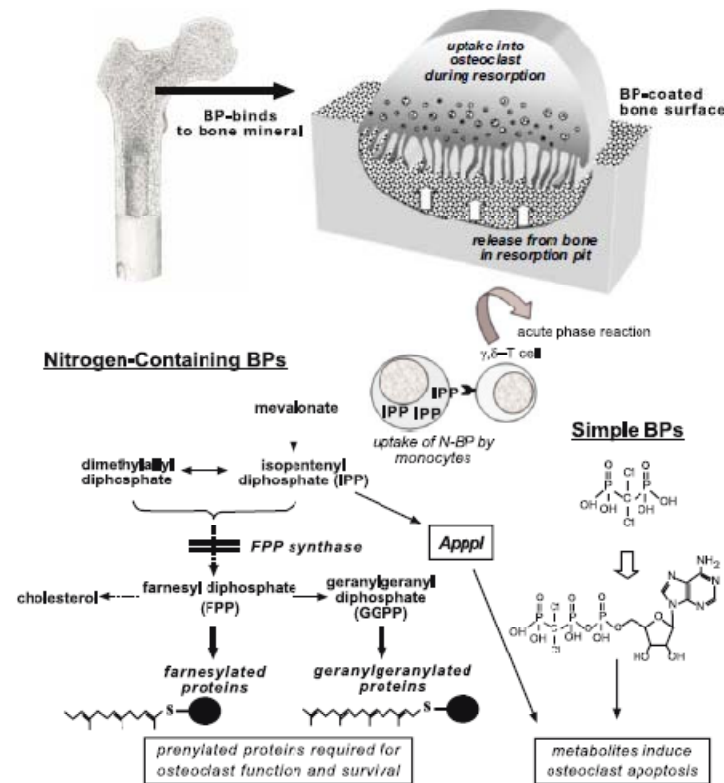
- Looks like PPI
- High affinity for Ca
- R2 side chain determines potency

# Bisphosphonates

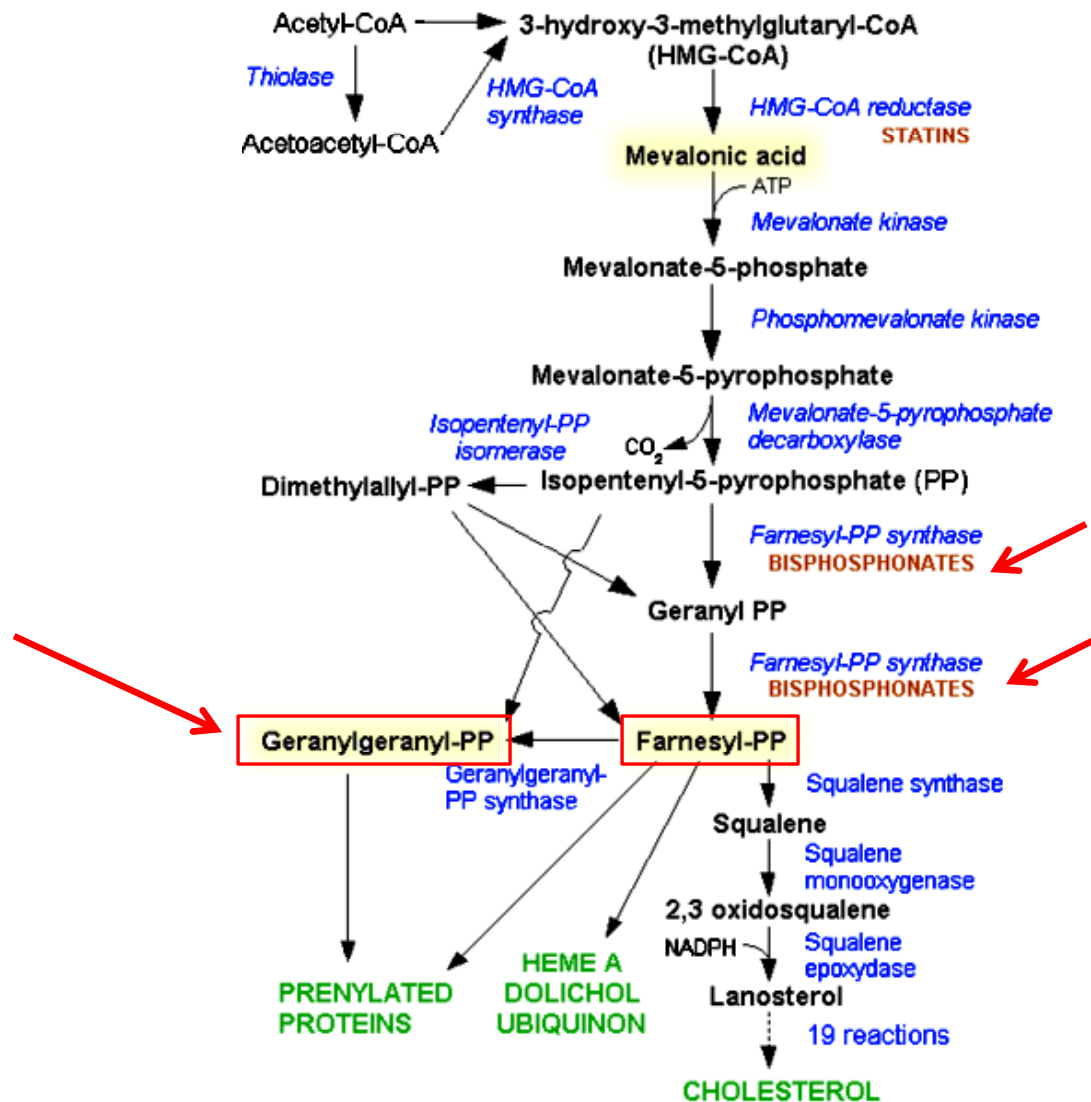
- Not thought to act on osteoblasts
  - No change in proliferation in 48-96 hours in normal osteoblasts.
  - Bone marrow stromal cells: improvement in differentiation to osteoblasts.
- Thought to act to poison osteoclasts
  - Apoptosis
  - Loss of ruffled border

# Bisphosphonates

- 1<sup>st</sup> generation act to inhibit ATP
- 2<sup>nd</sup> and 3<sup>rd</sup> generations act on mevalonate pathway



# Mevalonate Pathway



What is the evidence that BPs  
works in OI?

# How good is the evidence?

- Sakkars, 2004      olpadronate
- Gatti, 2005      neridronate      1/3 quit
- Seikaly, 2005      alendronate
- Letocha, 2005      pamidronate      +/- GH
- Antoninezzi, 2006      neridronate      infants

# How good is the evidence?

- Five Level 2 Studies in the literature
  - Less than 100 patients
  - Different bisphosphonates/doses used
  - Different age spectrum: infants v. children
  - Mixed population (phenotypes of OI)
  - Many under powered for fractures
  - **ONLY 1/5 control for orthopedic procedures**

# Sakkers, Lancet 2004

“routine care was administered throughout the study (fracture treatment, intramedullary rodding, corrective osteotomies and scoliosis surgery)”

Drug treatment n=16

Control n=18

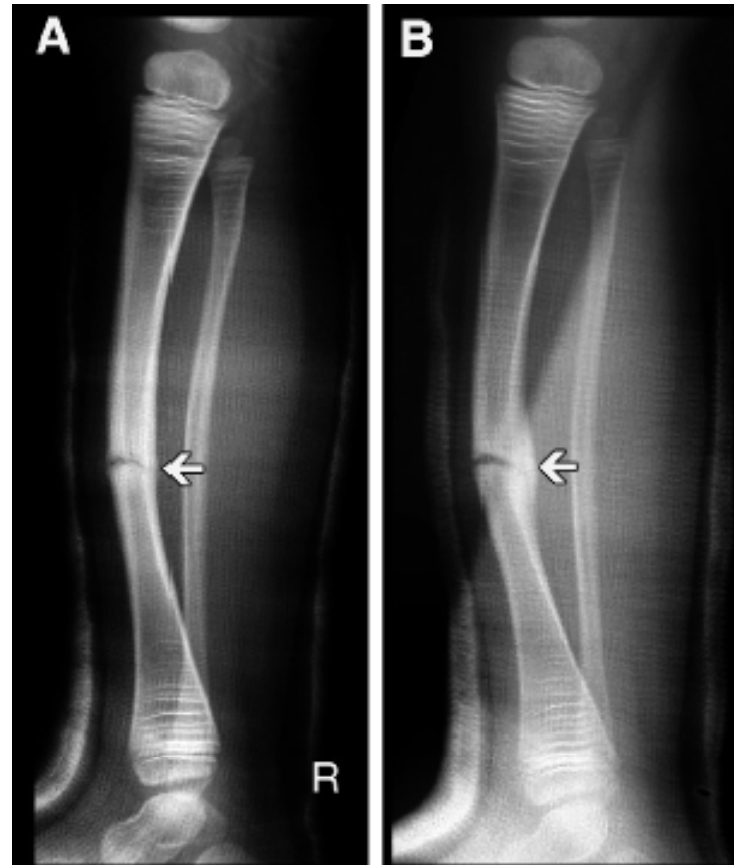# Cochrane Collaboration, 2008

- Meta - analysis
- Significant improvement in BMD IV or Oral
- Unclear if BMD is a surrogate for fractures
- Fracture, growth, bone deformity, mobility, pain ???
- Risks unknown

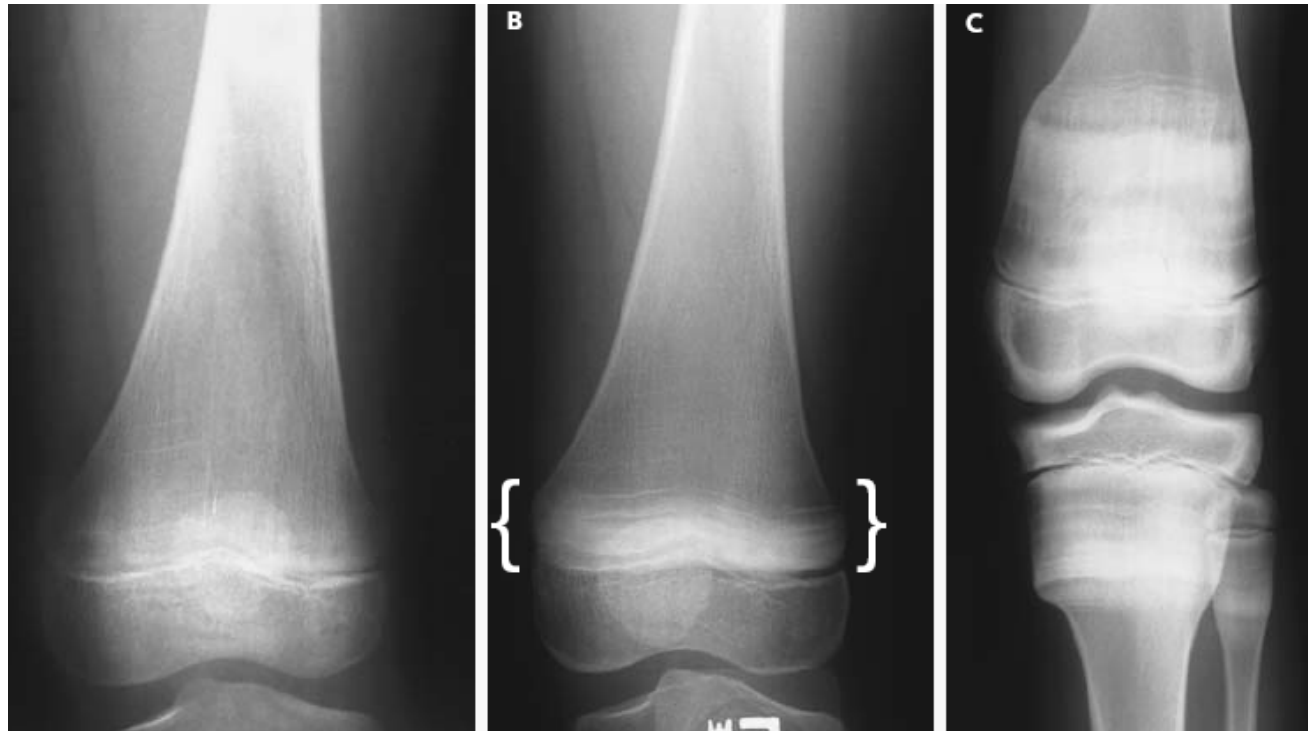
What are the complications of bisphosphonates?

## Delayed Osteotomy but Not Fracture Healing in Pediatric Osteogenesis Imperfecta Patients Receiving Pamidronate

Craig FJ Munns,<sup>1</sup> Frank Rauch,<sup>1</sup> Leonid Zeitlin,<sup>1,2</sup> François Fassier,<sup>3</sup> and Francis H Glorieux<sup>1</sup>



# Whyte M. NJM, 2003

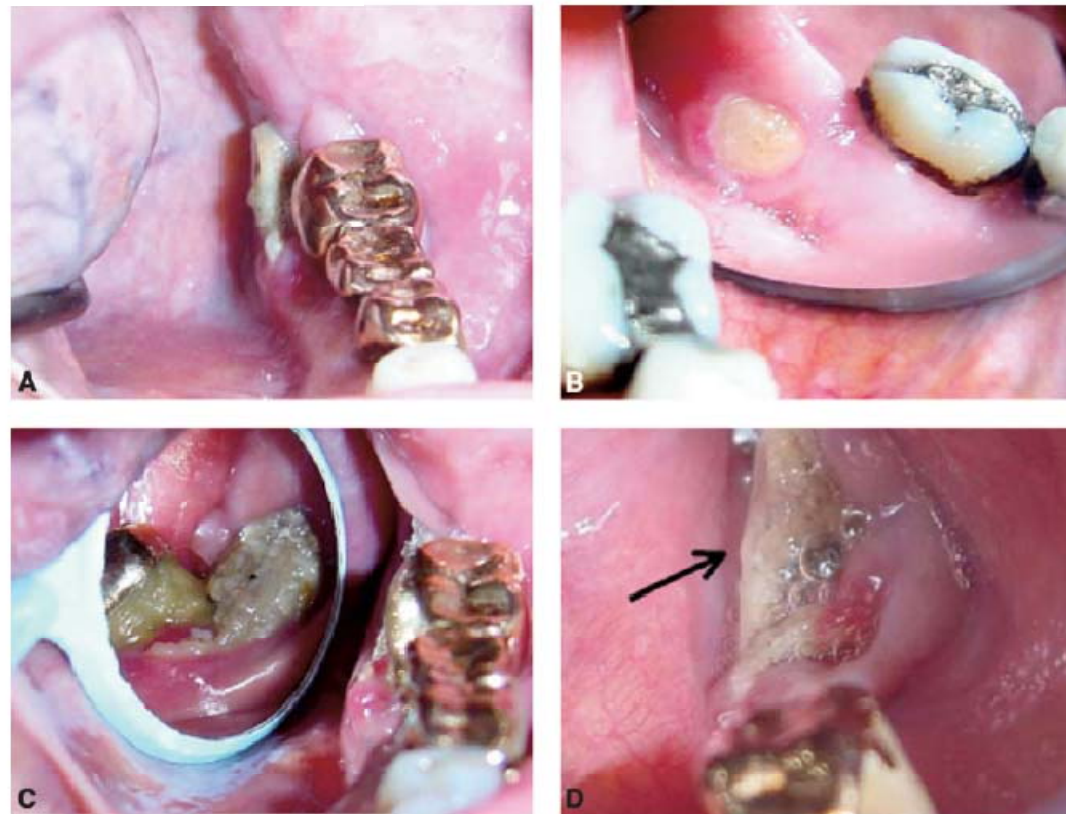


# Bisphosphonate-Associated Osteonecrosis Mandibular and Maxillary Bone

*An Emerging Oral Complication of Supportive Cancer Therapy*

Cesar A. Migliorati, D.D.S., M.S., Ph.D.<sup>1</sup>  
Mark M. Schubert, D.D.S., M.S.D.<sup>2,3</sup>  
Douglas E. Peterson, D.M.D., Ph.D.<sup>4,5</sup>  
Luis Marcelo Seneda, D.D.S.<sup>6</sup>

CANCER July 1, 2005 / Volume 104 / Number 1



**FIGURE 1.** Patient 11: Spontaneous necrotic bone at the mylohyoid plate present for months in a patient with metastatic breast carcinoma taking zoledronic acid. (A) Initial presentation on the left mandible. (B) Initial presentation on the right mandible. (C) Progress of bone exposure 1 year later. Bone necrosis and secondary infection on the left mandible are present after extraction of tooth 18 and part of the fixed bridge. (D) Left mandible 1 month before patient's death.

Q: A 6 month old has a midshaft transverse femur fracture and known type 3 OI, the best treatment for this child is?

- A Open reduction and internal fixation with plate and screws
- B Spica cast
- C Telescopic IM rodding
- D Spica casting and IV pamidronate
- E Non telescopic IM rodding and PAM

Q: A 6 month old has a midshaft transverse femur fracture and rib fractures and a corner fracture of the tibia, the best treatment for this child is?

- A Immediate spica casting
- B Social services consult
- C CT head and body
- D Pamidronate
- E Skin Biopsy