

Pediatric Spinal Deformity

Idiopathic Scoliosis
Scheuermann Kyphosis
Congenital Spine Deformity

Paul D. Sponseller MD
Johns Hopkins University

Definitions

- Lateral curvature $>10^\circ$ with rotation of the spine
- Types of scoliosis include:
 - Infantile: 0 to 3 years of age
 - Juvenile: 4 to 9 years of age
 - Adolescent: 10 years of age to maturity

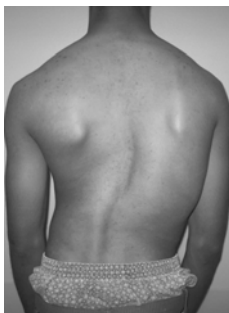
Objectives

- Diagnose common spinal deformities
- Know indications for bracing and surgery
- Make decisions from knowledge of natural history

Prevalence

- 2% to 3% for curves $>10^\circ$
- 0.3% for curves $>20^\circ$
- 0.1% for curves $>40^\circ$
- Male to female ratio is 1.4:1 for adolescent curves $>11^\circ$ to 20°
- Males are much less likely to progress
- Infantile and juvenile types are more rare

Idiopathic Scoliosis Diagnosis and Treatment Options



Back Pain and Scoliosis

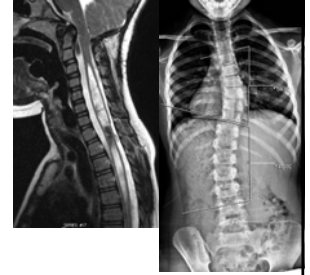- Present 23% at time of initial evaluation
 - 9% additionally during follow-up visit
- Identifiable cause rarely found
 - Spondylolysis
 - Scheuermann's disorder
 - disk, syrinx, or tumor
- Extensive *initial* work up not indicated

Etiology

- Positive family history found in 30% of adolescents
- Autosomal dominant with incomplete penetrance

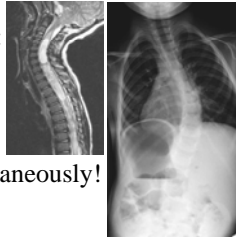Natural History- Juvenile

- MRI indicated
- 70% progress (brace)
- 50% require surgery



Natural History- Infantile

- MRI indicated to rule out Syring, Chiari, tether, etc
- Progression more likely if:
 - Present over age 1
 - RVAD >20
 - curve >40
- Many others resolve spontaneously!



AIS

- Natural History

- Progression related to maturity and curve size
- Risk of progression increases strongly at 25° in an immature patient
 - Main rationale for brace criteria
- Curves >45° may progress even after skeletal maturity
- Pulmonary compromise >75° to 100°

Infantile-Rx

- Cast then brace for progressive type < 4 y.o.
- Operate:
 - Curve > 60°
 - Failure of cast Rx
 - Growing rod or AP Fusion

Initial Evaluation

- Check for congenital, neurologic, and connective tissue disorders
- Assess flexibility, coronal and sagittal deformity, alignment (plumb), and shoulders
- Check gait, reflexes, and limb length inequality
- If pain is reported, quantify and localize

Management-AIS

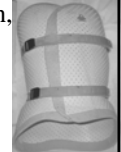
- Observation:
- Curves $<25^\circ$
 - Immature (Risser 0-2): Follow up in 4-6 mos
 - Mature patients (Risser 4-5): **No follow-up**
- Curves 25° to 45° in (Risser 4-5) girls:
Re-evaluate in 1 year

Brace Types (continued)

- Charleston Night Bending Orthosis
 - Single curves 25° to 35°



- There are many others brace types, including the Providence, Wilmington, Spine Cor.



Brace Indications

- 25° - 45° (Risser 0-1): Brace on initial evaluation
- 25° - 30° (Risser 2-3): Brace if documented progression $>5^\circ$
- 30° - 45° (Risser 2-3): Brace on initial evaluation
- Brace treatment for curves $>40^\circ$ to 45° has a lower success rate

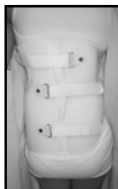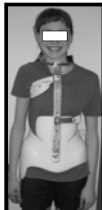CTQ

Brace Regimen

- 23 hours per day is ideal
- 16 to 23 hours may have some benefit
- Continue until maturity:
 - 2 years post-menarche
 - Risser 4 in females, Risser 5 in males
 - No significant gain in height

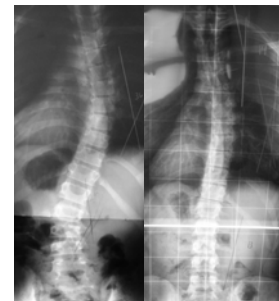Brace Types

- Thoracolumbosacral Orthosis (TLSO)
 - Current “gold standard”
- Milwaukee Brace
 - Indicated for curves with apex $>T8$



Brace results

- 65% progress $\leq 5^\circ$
- 7 year follow-up



Surgery

- Recommended for curves $> \sim 45^\circ$
 - Exception: Balanced double curves $> 55^\circ$ may be observed for progression
- Curve Patterns
 - King classified 5 types of *thoracic* curves to help identify *lumbar* curves that do not need surgery
 - Lenke classification covers all curve types and include the sagittal plane

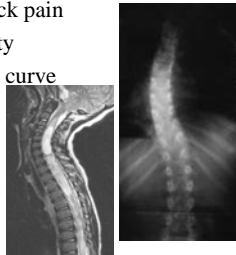Operative Management

- Thoracic and double major curves (King I-V):
 - Posterior fusion with segmental fixation is state-of-the-art
 - Many instrumentation types are equivalent

Preoperative Assessment

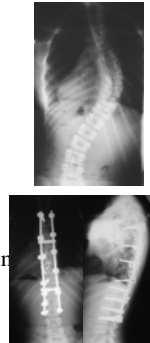- MRI indicated if:
 - Significant back or neck pain
 - Neurologic abnormality
 - Left LOWER thoracic curve
 - < 10 years of age

CTQ



Fusion Levels

- Neutrally rotated
- At or beyond end Cobb vertebrae
- Stable vertebra distally
- Never below L4 in adolescents
- Include significant upper curves
- Modify for sagittal plane factors
- Exceptions: Anterior or pedicle instrum



Risk of Crankshaft Phenomenon

- Before Peak Growth velocity
- Risser 0
- Open triradiate cartilages
- < 10 years of age

Consider anterior fusion or posterior pedicle fixation

King II Curves

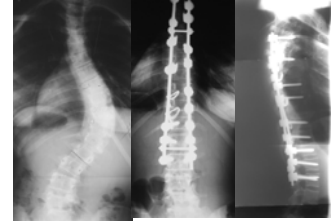
- Identified for selective thoracic fusion
- Thoracic to lumbar ratio ≥ 1.2
- Lumbar rotation, apical translation less
- No abnormal sagittal curve
- Fuse to stable vertebra
- Also called Lenke 1B and 1C

Lenke Classification

- 1- Main Thoracic
- 2. Double Thoracic
- 3. Double Major
- 4. Triple Major
- 5. TL/L
- 6. TL/L + Main thoracic

Pedicle Screws

- Better correction & maintenance
- Fewer levels
- ?crankshaft
- Cost, time

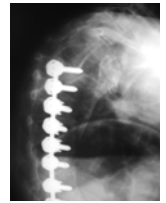

Lenke

- Criteria for structural curve: >25 on bend
- Thoracic Sagittal (+,N, -) and Lumbar coronal modifier (A,B,C)

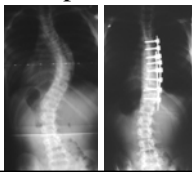Long-Term Effects

- Increased stress on adjacent disks
- May be alleviated by better sagittal contouring
- Not as big a problem above L3



Evolving Techniques

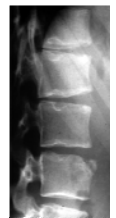
- Anterior instrumentation of thoracic spine
- Thoracoscopic release
- Thoracoscopic instrumentation



Scheuermann Kyphosis

Definition

- 3 vertebrae wedged > 5°
- Disc narrowing
- Endplate irregularity
- Schmorl's nodes
- May occur in thoracolumbar/ lumbar spine without kyphosis



Scheuermann Kyphosis

- Etiology: Unknown
- An osteochondrosis
 - disordered behavior of cartilage in response to load
 - in the growing spine

Differential diagnosis

- Postural roundback
 - generalized roundness
- Congenital Kyphosis
 - if bar not yet ossified
- Ankylosing spondylitis
- Spondyloepiphyseal dysplasia tarda
 - check other epiphyses
- Neurofibromatosis 1
- Trauma

Natural History

32 year f/u

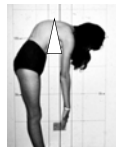- Kyphosis tends to increase
- More intense back pain
- Select lower activity levels
- No lowering of PFTs unless $> 100^\circ$
- No significant problems with self-esteem
- No interference with work
 - Murray and Weinstein JBJS 1993

Conservative Treatment -the mainstay

- Exercises may relieve pain
 - hamstring stretching
 - extensor strengthening
 - do not help the deformity
- Bracing
 - improves the deformity
 - also may help pain
 - Mean final correction 10-15 degrees

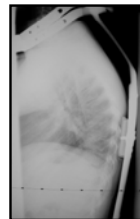
Signs and Symptoms

- Adolescent onset
- Focal kyphosis
- Tight hamstrings
- Often a mild scoliosis
- Back pain in thoracic or lumbar regions
- Appearance problems
 - often least talked-about
 - bother some but not others



Brace Treatment indications

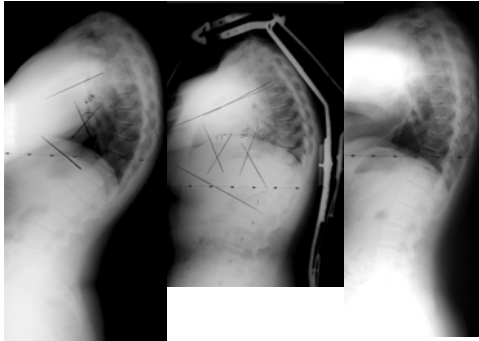
- Pain or appearance problem
 - explain natural history & window of opportunity
- Curve < 70 degrees
- Risser sign ≤ 3
- Flexibility



CTQ

Brace Result

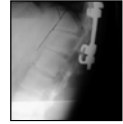
- 10-20° permanent correction



Surgery

-complications

- Superior mesenteric artery syndrome
- Junctional kyphosis above or below rods
- Rod dislodgement
- Pseudarthrosis
- Rod fracture
- Neuro damage
- ...more likely to have problems than idiopathic scoliosis



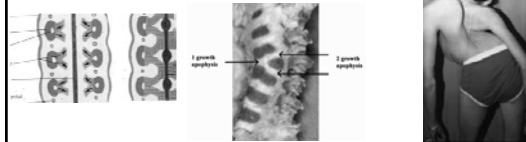
Surgery

- Posterior spinal fusion = gold standard
- Shorten posterior column
 - resect elongated facets at apex
 - minimize dissection at upper & lower ends
- Compression instrumentation
 - larger diameter rods better

Congenital Spine Deformity

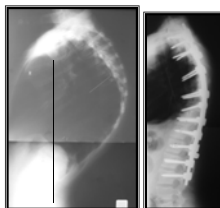-Definition

- Deformity due to primary vertebral malformation
- Rule out infantile idiopathic scoliosis and neurogenic scoliosis



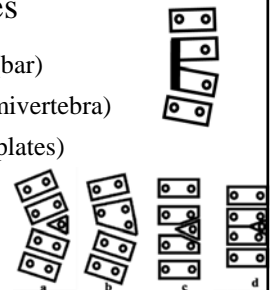
Surgery

- Do not overcorrect- get to 40-50°
- Fuse all levels in curve; sagittal stable zone
- T2-L1 or L2 most common levels
- ? Anterior release if bends to < 50°



Types

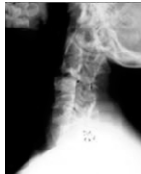- Failure of segmentation (bar)
- Failure of formation (hemivertebra)
 - Segmented (2 growth plates)
 - Semisegmented
 - Unsegmented
- Incarcerated: Not producing curve



Associations

1/3 have other anomalies (Winter)

- VA(C)TER(L)
 - V most common
- Goldenhar
- Myelodysplasia: 20%
- Klippel-Feil
 - Congenital cervical fusion



Imaging

- Check GU tract
 - Renal ultrasound and creatinine
 - MRI

CTQ

Congenital Kyphosis

- Type I: Failure of formation (wedged vertebrae)
 - Rapidly progressive
 - May produce paraplegia
- Type II: Failure of segmentation
 - Less progressive
 - Does not produce paraplegia

CTQ

Prognosis

- Most patients have slight short stature
- 70% risk of progression
 - 50% to 50°
- Progression greatest after 10 years of age
- May cause cor pulmonale
- Congenital kyphosis may cause paralysis

Imaging

- Magnetic resonance imaging (MRI) shows abnormalities in 26%
 - Syrxinx
 - Chiari
 - Tether or lipoma
- When to order?
 - When exam abnormal or patient going to operating room for corrective procedure

CTQ

Spinal Growth

- Averages 0.07 cm/year per segment
- Anomalous segments will never have this degree of growth
- Spinal growth is two-thirds complete by age 6

CTQ

Prognosis

- Bar more progressive than hemi (in the coronal plane)
- Lumbar anomalies are more progressive than thoracic

Surgical Options

- Posterior
- Anterior and posterior (combination)
- Convex hemiepiphysodesis
- Vertebral excision
- Instrumentation

Bracing

- No proven value for congenital curves

Posterior Fusion

- Simplest and safest technique
- Cast correction
 - Or instrumentation
- Thick fusion mass
- Indications:
 - Small curves
 - Limited growth potential
 - Type II kyphosis $<50^\circ$

Indication for Surgery

- Unacceptable deformity
- Bar + contralateral hemivertebra
- Progression $> 10^\circ$

Convex Hemiepiphysodesis

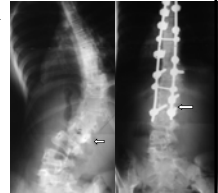
- Deformity correction with growth
- Prerequisites:
 - Concave growth potential
 - ≤ 5 involved vertebrae
 - $<70^\circ$ curve
 - ≤ 6 years of age
- Maximum correction 10° to 15°

Combined Anterior/Posterior Fusion

- Prevents crankshaft and pseudarthrosis
- Indications:
 - Large growth potential
 - Type I kyphosis $>50^\circ$

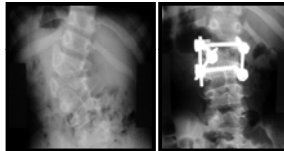
Instrumentation

- Increased correction but increased risk
- Possible uses:
 - Avoid cast in older patient with in situ fusion
 - Achieve correction of mobile segments
 - Stabilize after vertebra excision



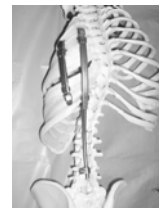Hemivertebra Excision

- Indication: Unacceptable deformity
- Prerequisites:
 - Accessible vertebra
 - Balance achievable
- Risks: Neurologic
 - Recent series document good results



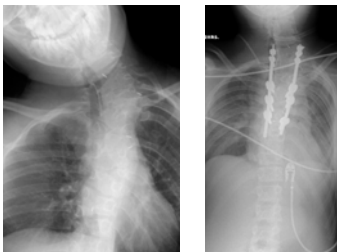
VEPTR

- Vertically Expandable Prosthetic Titanium Rib
- Indicated for fused ribs
- Leverage may promote growth of hypoplastic spinal region



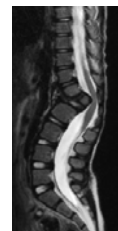Hemivertebra Excision

- Most Deforming at upper and lower ends



Congenital Kyphosis Treatment

- Type I (hemi):
 - $<55^\circ$: Posterior fusion
 - $>55^\circ$: Anterior + Posterior fusion
- Type II (ant. bar):
 - $<55^\circ$: Posterior fusion
 - $>55^\circ$: Anterior osteotomies and posterior fusion



CTQ

- The most severe and rapidly progressive form of congenital scoliosis is

1-block vertebra.

2-semisegmented hemivertebra.

3-fully segmented hemivertebra.

4-unilateral unsegmented bar.

5-unilateral unsegmented bar with contralateral hemivertebra.

...Thank you



- The mean age of triradiate cartilage closure in girls and boys is

- 10 and 12

- 11 and 12

- 12 and 13

- 12.5 and 13.5

- 13.5 and 14.5

A 13-year-old girl has scoliosis. She has long, slender fingers. When she grasps her left wrist with her right hand, the thumb covers the fifth fingernail. She wears glasses for myopia. Preoperative work-up should include

1- an echocardiogram.

2- neurofibromin testing.

3- a serum fibrillin level.

4- an MRI scan of the spine.

5- a urine mucopolysaccharide screen.

