

### AVN- important topics

- Etiology/pathogenesis
  - Demographics
  - Classification
- Treatment options

### Osteonecrosis Occurs In The 'At Risk' Patient

#### Associated Condition

- |                    |     |                   |           |
|--------------------|-----|-------------------|-----------|
| Steroids*          | CTQ | Gout              | Radiation |
| Alcohol Abuse*     |     | Coagulopathies    |           |
| Smoking            |     | Metabolic Disease |           |
| Lipid Disturbances |     | Major Trauma      |           |

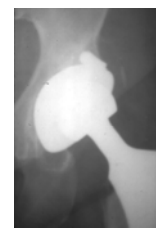
### Coagulopathies

- Lupus anticoagulant
- Protein C or S deficiency
  - Factor V leiden
  - Lipoprotein A
  - Homocysteine
- Anticardiolipin antibody
  - Antithrombin III

### The Face of Osteonecrosis



21 years old



15 years after THR

Average Age 38  
25% <25 years old

### All Treatments Are Not Equal

- Success Rate
- Morbidity
- Potential Complication
- Impact on Subsequent THR

### All Osteonecrosis is Not Equal

#### Important Variables

- Stage
- Size
- Age
- Underlying Disease

### Natural History of No Treatment

(Observation, Protected Wt. Bearing)

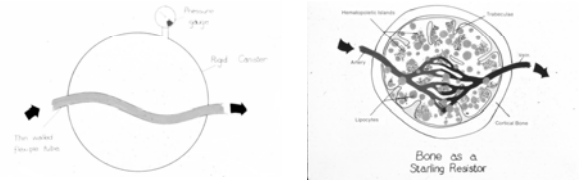
21 studies      819      22.7% Success  
[0-32]

Usually 2-4 year F/U

Mont et al. 1995

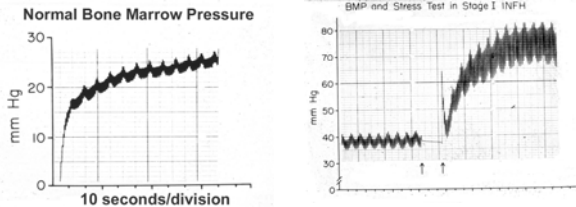
### Exact Pathogenetic Pathway Unknown

Bone Functions as Starling Resistor



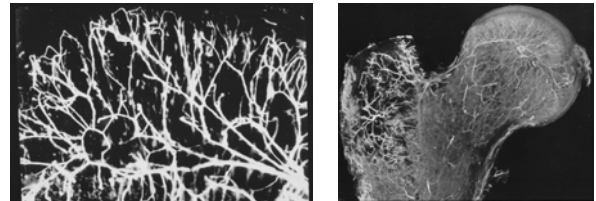
CTQ

### Increase BMP Hallmark of Osteonecrosis



### Pathogenesis of Osteonecrosis

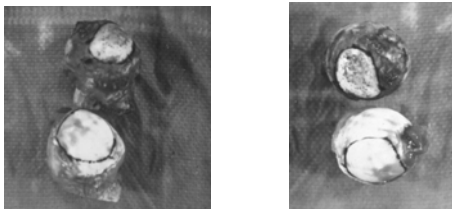
Coagulation Defect May Be Final Common Path



AVN occurs in the convex ends of long bones

CTQ

### Biomechanics of Collapse in Osteonecrosis



AP View

Top View

OA & ON - Same area of collapse/wear

### Osteonecrosis Several Staging Systems

Ficat  
Steinberg  
ARCO  
Marcus/Enneking

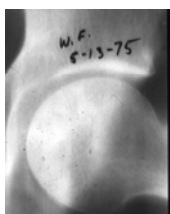Pre-collapse vs.  
Post collapse

I & II Precollapse in ALL

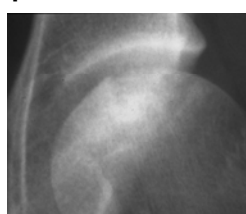CTQ

### Stage III Osteonecrosis

The watershed between  
cure and palliation



Stage II "Intact"

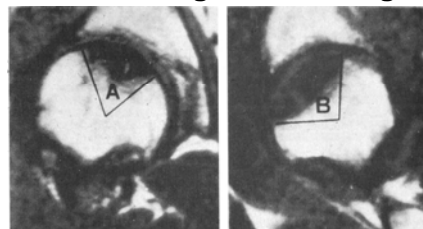


Stage III "it's broke"

CTQ

### Osteonecrosis Staging

Kerboul angle:  $>200 =$  large



A + B = Kerboul Angle

### Osteonecrosis Staging

Size of Lesion

A: small  $<15\%$

B: medium 15 to 30%

C: large  $>30\%$

### The Goal of Treatment in Osteonecrosis

#### Preserve the Femoral Head

- Core Decompression
- Osteotomy
- Free Fibular Graft
- Bone Graft
- Femoral Head Resurfacing

### Core Decompression

Simple, low cost  
Low morbidity  
Controversial

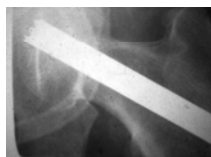### Core Decompression

- Moderately effective for precollapse disease (70%)
- Recommended for asymptomatic AVN of the hip

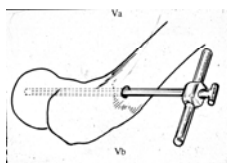
CTQ

### Core Decompression

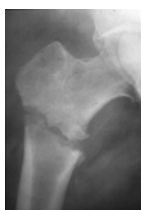
Avoid The Pit Falls



Biplane Image



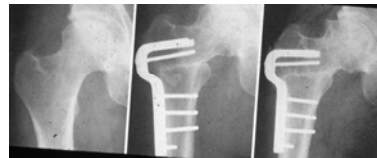Entry @ Lat. Flare



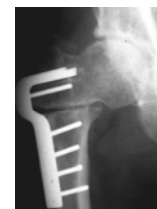Crutches 6 wks.

CTQ

### Osteotomy for Osteonecrosis



Deforms the Femur



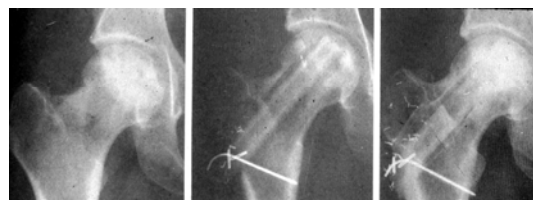Sig. Morbidity

Suitable for some small Stage III -sugioka, or varus types

### Indication for Osteotomy

- Smaller lesion (kerboul <200)
- Preserved region of cartilage than can be rotated into a weight bearing position

### Free Vascular Fibular for Osteonecrosis



Donor morbidity (25%) CTQ  
Better in stage III than core

### Free Vascular Fibular for Osteonecrosis

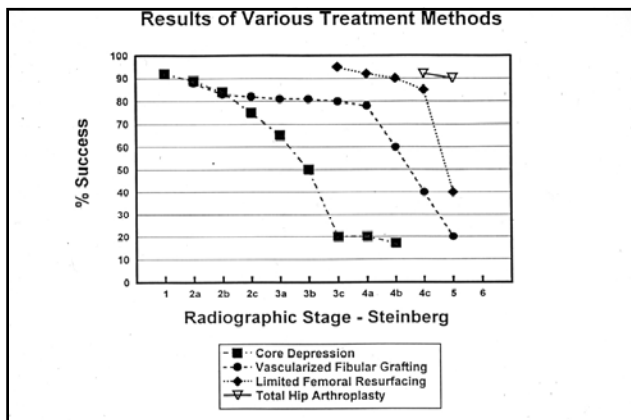
103 Hips

Stage II	89%
Stage III	77%
Stage IV	55%
Stage V	65%
5 Year Survival	

Urbaniak 1996 JBJS

### INCIDENCE

- HIPS>KNEES>SHOULDERS>ANKLES
- Check hips for asymptomatic lesions if other joint presents first (multifocal AVN)



**Transient Osteoporosis of the Hip**

CTQ

- Seen in younger men
- Extensive edema seen on T2 MRI
- No “double line” sign
- Not associated with AVN risk factors
- Resolves with protected weight bearing
- May progress to AVN

**Take home points**

- AVN occurs in the at risk patient
- Average age is 34
- Core decompression for stage II
- Don't forget to check the hips
- Core hip even if asymptomatic
- Temporizing procedures for stage III and under 40
- THR over 40

**Management of Osteonecrosis of The Knee**

SPONK is Not Osteonecrosis CTQ

MRI of SPONK

**SPONK**

---

Differentiate from ON  
 Medial femoral condyle CTQ  
 Mostly women >60 CTQ  
 ? Microfracture CTQ  
 Possible benign course CTQ

Ecker & Lotke  
 J. Am Acad Orthop Surg 1994

**Treatment of SPONK**

---

79 Patients

Group I - Bone scans, x-ray-negative

Group II - Small lesions <1/3 width of condyle

Group III - Large lesions >50% diameter of condyle

I & II - Conservative

III - Rapid progression

Ecker & Lotke  
 J. Am Acad Orthop Surg 1994

### SPONK vs AVN of the Knee

#### SPONK

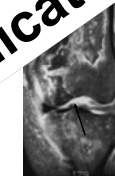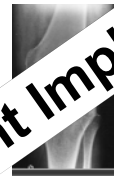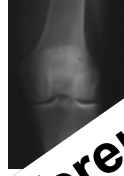- age > 65
- one condyle
- unilateral
- only knee
- no risk factors

#### AVN

- age < 45
- multiple condyles
- bilateral
- other joints
- risk factors (steroids, alcohol)

### Staging ON Knee

Same Criteria as



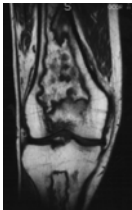
Different Implications

Stage II  
X-ray pos  
No Collapse

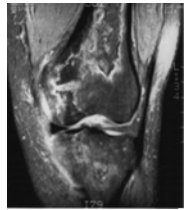Stage III  
Early Collapse

Stage IV  
Arthritis

### All ON Knee Not the same



Metaphyseal  
Rarely collapse



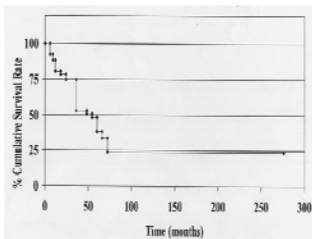
Epiphyseal CTQ

### Treatment Options

- Non-Operative
- Core Decompression
- Arthroscopic Debridement
- OATS/Mosaicplasty
- Uni-TKR
- TKR

### Treatment of Atraumatic ON Knee

41 Treated initially non-operative  
8 (20%) clinical success @ 8 y. follow

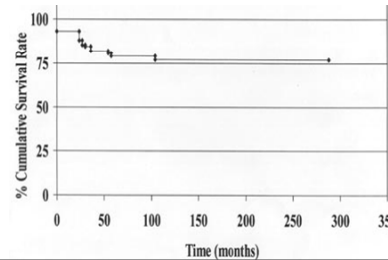


CTQ

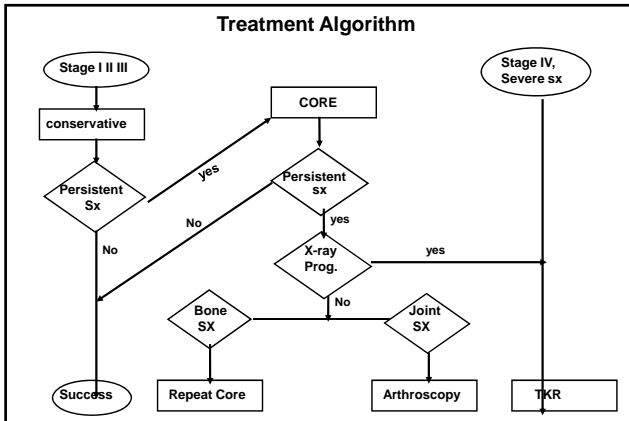
Mont et al  
JBJS 2000

### Treatment of Atraumatic ON Knee

91 Knees core decompression  
79% Good or excellent @ 7 year follow



Mont et al  
JBJS 2000



**Treatment of Atraumatic ON Knee**

---

**TKR**

**Never do Uni (Uni is good for SPONK)** CTQ

**Always use cement** CTQ

**When bone terrible use stems** CTQ